

Author Ke
 Vol Pa

HOME HELP FEEDBACK SUBSCRIPTIONS ARCHIVE SEARCH TABLE OF CONTENTS

[Advanced]

Heart 2000;84:52 (July)

Images in cardiology

Visualising fatty deposits in familial arrhythmogenic right ventricular cardiomyopathy by magnetic resonance imaging

This 70 year old man had familial arrhythmogenic right ventricular cardiomyopathy (ARVC) with recurrent ventricular tachycardia since the age of 41. The diagnosis of ARVC was made on the basis of recurrent, refractory ventricular tachycardia, echocardiographic findings, a positive family history, and the detection on magnetic resonance imaging (MRI) of fatty deposits in the right ventricle. Transoesophageal echocardiography (top) showed a dilated right ventricle and focal thinning of the right ventricular wall apicoseptally and apicolaterally with two localised bulges in the right ventricular wall (arrows) (RV, right ventricle; LV, left ventricle). MRI (bottom) showed an almost akinetic thin wall of the right ventricle with fatty deposits, confirming the diagnosis of familial ARVC. Fatty deposits are seen in the atrioventricular groove (1); the right ventricular free wall is completely replaced by fatty tissue (2), which also extends to the apex and part of the lateral wall of the left ventricle (3); pericardium is seen at the base of the left and right ventricles (4); slow flow artefacts are particularly predominant in the right atrium (5).

MRI is a non-invasive method for detecting isolated fatty deposits in the myocardium of the right ventricle. The abnormalities shown by MRI are generally the starting point for the observed ventricular tachycardias. The differential diagnosis has to take account of Uhl's anomaly, which also involves localised involvement of the right ventricle. In contrast with ARVC, wall areas in Uhl's anomaly are characterised by a complete absence of myocardial cells. In such wall sections the endothelium and epithelium are in direct apposition.



This Article

- ▶ [Submit a response](#)
- ▶ [Alert me when this article is cited](#)
- ▶ [Alert me when eLetters are posted](#)
- ▶ [Alert me if a correction is posted](#)

Services

- ▶ [Email this link to a friend](#)
- ▶ [Similar articles in this journal](#)
- ▶ [Similar articles in PubMed](#)
- ▶ [Add article to my folders](#)
- ▶ [Download to citation manager](#)

Google Scholar

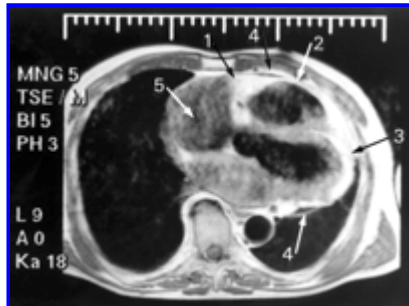
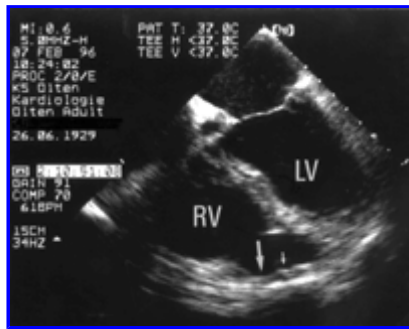
- ▶ [Articles by IMMER, F. F](#)
- ▶ [Articles by SANER, H.](#)
- ▶ [Articles citing this Article](#)

PubMed

- ▶ [PubMed Citation](#)
- ▶ [Articles by IMMER, F. F](#)
- ▶ [Articles by SANER, H.](#)

Related Collections

- ▶ [Cardiomyopathy](#)
- ▶ [Other imaging techniques](#)



View larger version (240K):

[\[in this window\]](#)

[\[in a new window\]](#)

FRANZ F IMMER, MICHEL ROMANENS, HUGO SANER

© 2000 by Heart

This Article

- ▶ [Submit a response](#)
- ▶ [Alert me when this article is cited](#)
- ▶ [Alert me when eLetters are posted](#)
- ▶ [Alert me if a correction is posted](#)

Services

- ▶ [Email this link to a friend](#)
- ▶ [Similar articles in this journal](#)
- ▶ [Similar articles in PubMed](#)
- ▶ [Add article to my folders](#)
- ▶ [Download to citation manager](#)

Google Scholar

- ▶ [Articles by IMMER, F. F.](#)
- ▶ [Articles by SANER, H.](#)
- ▶ [Articles citing this Article](#)

PubMed

- ▶ [PubMed Citation](#)
- ▶ [Articles by IMMER, F. F.](#)
- ▶ [Articles by SANER, H.](#)

Related Collections

- ▶ [Cardiomyopathy](#)
- ▶ [Other imaging techniques](#)

[HOME](#) [HELP](#) [FEEDBACK](#) [SUBSCRIPTIONS](#) [ARCHIVE](#) [SEARCH](#) [TABLE OF CONTENTS](#)